Neuroscience Letters 657 (2017) 11–15

Contents lists available at ScienceDirect

Neuroscience Letters

journal homepage: www.elsevier.com/locate/neulet

Research article

A novel *PSEN1* (S230N) mutation causing early-onset Alzheimer's Disease associated with prosopagnosia, hoarding, and Parkinsonism

John M. Ringman[a,b,*], Maria Casado[b], Victoria Van Berlo[c], Judy Pa[a,d], Nelly Joseph-Mathurin[e], Anne M. Fagan[f], Tammie Benzinger[e], Randall J. Bateman[f], John C. Morris[f]

[a] Department of Neurology, Keck School of Medicine of the University of Southern California, 1540 Alcazar Street, Suite 209F, Los Angeles, CA, 90033, USA
[b] Mary S. Easton Center for Alzheimer's Disease Research, David Geffen School of Medicine at UCLA, 710 Westwood Plaza, Room C-224, Los Angeles, CA 90095-1769, USA
[c] Semel Institute for Neuroscience and Human Behavior, 695 Charles Young Drive South, Los Angeles, CA 90095, USA
[d] Mark and Mary Stevens Neuroimaging and Informatics Institute, Keck School of Medicine of the University of Southern California, 2025 Zonal Ave, Los Angeles, CA 90033, USA
[e] Mallinckrodt Institute of Radiology, Washington University in St. Louis, 510 S. Kingshighway Blvd. #1610, St. Louis, MO, 63110, USA
[f] Department of Neurology, Washington University in St. Louis, 660 S. Euclid Ave, St. Louis, MO, 63110, USA

HIGHLIGHTS

- We describe a novel mutation in PSEN1 associated with early-onset Alzheimer's disease.
- The index patient had the atypical features of prosopagnosia, hoarding behavior, and Parkinsonism.
- We demonstrate segregation with the disease and in silico evidence for it's pathogenesis.
- We add to knowledge regarding the genetic basis of autosomal dominant Alzheimer's disease and it's clinical spectrum.

ARTICLE INFO

Article history:
Received 13 June 2017
Received in revised form 21 July 2017
Accepted 25 July 2017
Available online 29 July 2017

Keywords:
PSEN1
Novel
S230N
Prosopagnosia
Hoarding
Parkinsonism
Visual agnosia

ABSTRACT

We describe clinical and biomarker findings in an index patient with the onset of Alzheimer's disease (AD) symptoms at age 57 and a family history consistent with an autosomal dominant pattern of inheritance. She had the atypical early features of visual agnosia and prosopagnosia followed by hoarding behavior and Parkinsonism. Structural MRI revealed global atrophy that was most severe in the lateral temporal lobes and insular cortex bilaterally. CSF biomarker assessment showed Aβ42, p-tau$_{181}$, and total tau levels consistent with AD. Genetic assessment revealed a novel mutation in the *PSEN1* gene (S230N) in the index patient and her affected brother which was absent in her two clinically unaffected and AD-biomarker negative sisters. The serine residue at codon 230 in *PSEN1* is highly conserved across species and in *PSEN2*, providing strong evidence for its pathogenicity in this family.

© 2017 Elsevier B.V. All rights reserved.

1. Introduction

Mutations in the *PSEN1*, *APP*, and *PSEN2* genes cause autosomal dominant Alzheimer's disease (ADAD) which is typically of relatively young onset. Mutations in *PSEN1* are the most common with at least 219 pathogenic mutations in this gene having been described (http://www.molgen.ua.ac.be/admutations). In this report we describe a probably pathogenic novel *PSEN1* mutation with prosopagnosia, hoarding behavior, and Parkinsonism associated with severe bilateral lateral temporal lobe and insular atrophy.

* Corresponding author at: Department of Neurology, Keck School of Medicine of USC, Center for the Health Professionals, 1540 Alcazar Street, Suite 209F, Los Angeles, CA 90033, USA.
E-mail address: John.ringman@med.usc.edu (J.M. Ringman).

http://dx.doi.org/10.1016/j.neulet.2017.07.046
0304-3940/© 2017 Elsevier B.V. All rights reserved.

2. Materials and methods

We report the clinical presentation and results of the clinical and genetic assessments for an index patient, clinical descriptions of the affected mother and brother, and genetic results from the affected brother and two unaffected sisters. The index patient and two unaffected sisters underwent comprehensive evaluations as part of their participation in the Dominantly Inherited Alzheimer Network (DIAN, NIA UF1 AG032438, Principal Investigator, RJ Bateman) [1]. CSF levels of p-tau$_{181}$ (p-tau) and total tau were measured via Luminex based methods using multiplexed xMAP technology (AlzBio3, Fujirebio, formerly Innogenetics, Ghent, Belgium) and levels of CSF Aβ42 were measured by plate-based ELISA (Fujirebio, formerly Innogenetics, Ghent, Belgium). Metabolic imaging with [18F]Fluorodeoxyglucose positron emission tomography (FDG-PET) was performed for the index patient and the two clinically unaffected sisters with a 3D dynamic acquisition beginning 40 min after a bolus injection of approximately 5 mCi of [18F]FDG and lasted for 20 min. Amyloid imaging was performed on the two clinically unaffected sisters with a bolus injection of approximately 15 mCi of [11C]Pittsburgh Compound B (PiB). Dynamic imaging acquisition started either at injection for 70 min or 40 min post-injection for 30 min. For analysis, the PiB PET data between 40 to 70 min were used. PiB+ (positivity) was defined as a mean cortical binding potential (MCBP) of 0.18 or higher [2].

3. Results

3.1. Clinical description of the index patient

The index patient is a Caucasian female nurse of northern European extraction with 18 years of education who, at age 57, underwent immunization for herpes zoster after which she became acutely ill with radiculopathic symptoms to the point of being bed-ridden. She returned to work but was then noted to have the gradual onset and progression of memory loss, slowness consistent with bradykinesia, and difficulty recognizing people by their faces though recognition by voice was retained. She had increased difficulty reading, found to be holding a book upside down at one point while attempting to do so. She tended to follow her husband around when out, once errantly following a stranger in this manner. MRI was performed at age 59 that was interpreted as showing “mild to moderate ventriculomegaly with prominence of the subarachnoid spaces, particularly in the temporal lobes and to a lesser extent in the frontal lobes”. She stopped working again at age 60 to help take care of her grandchildren. However, she could not return to work subsequently due to worsening cognitive deficits. At age 62 she was found to be “stashing” things in unusual places around the house and was considered a “compulsive organizer” by her husband who had to become more involved in the household affairs at that point. She also was becoming involved in minor motor vehicle accidents at that time so stopped driving. Blood tests done to evaluate for reversible causes of cognitive impairment were performed which were unrevealing. At age 63, jerking movements consistent with myoclonus began to become evident, difficulties with facial recognition and dressing apraxia were documented and her Montreal Cognitive Assessment [3] score was 16/30. Her past medical history was significant for mitral valve prolapse, osteopenia, endometriosis, a cholecystectomy, hysterectomy and oophorectomy. She had also had depression since her 30 s for which she had been treated with multiple different antidepressants.

When seen by the authors at age 65 she had headaches and ongoing depression as well as anxiety, delusional misidentification, irritability, and purposeless repetitive movements. There was no evidence of dream-enactment behavior. On physical examination she was noted to have mild bradykinesia and hypomimia, a moderate bilateral action tremor, arm rigidity (slight on the right, mild to moderate on the left), severely impaired finger tapping on the left, moderate bilateral leg rigidity, and slow but independent ambulation. She had saccadic smooth pursuit eye movements, and myoclonic jerks of the face and left arm were noted. Reflexes were diffusely brisk at 3+ throughout except in the lower left extremity where the patellar and Achilles reflexes were 4+. On cognitive

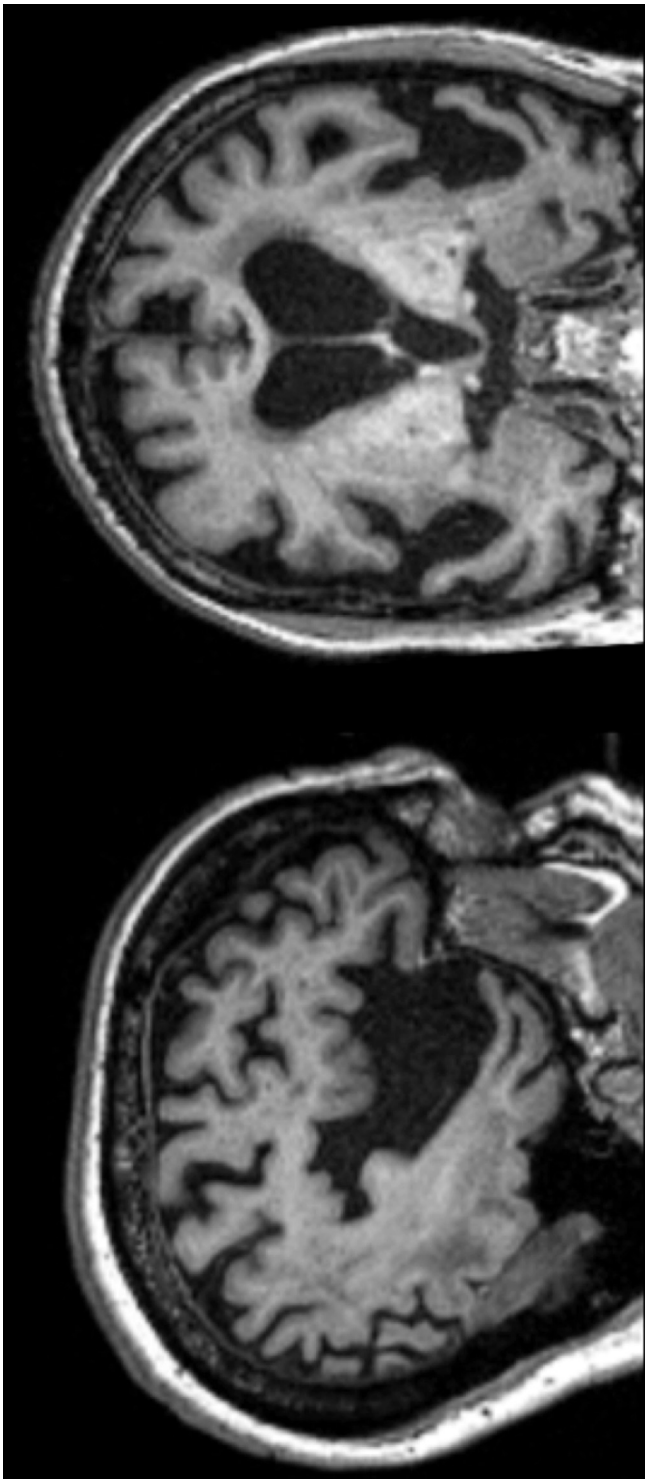

Fig. 1. Sagittal and coronal T1-weighted image of the index patient at age 65 showing global atrophy most severe in the lateral temporal lobes and insular cortex bilaterally.

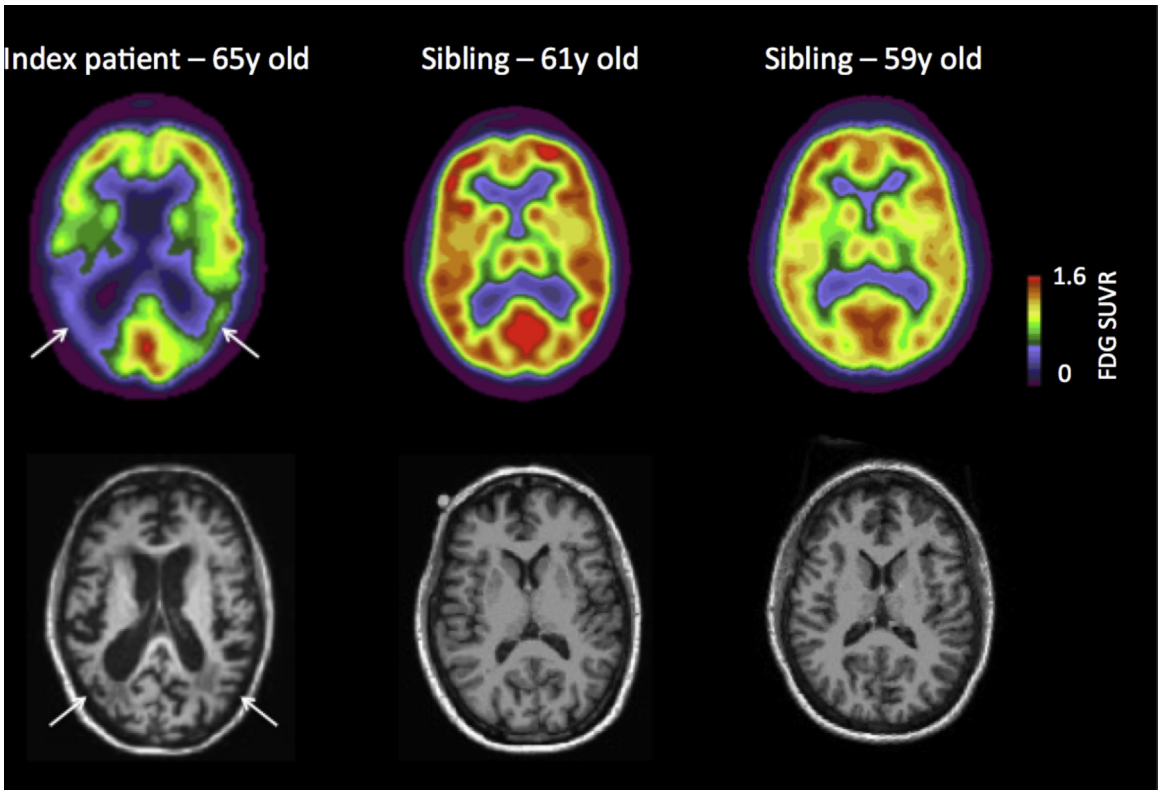

Fig. 2. Axial FDG-PET and T1-weighted MR images of the index patient and her unaffected siblings. The index patient presented hypometabolism and severe atrophy compared to her siblings (white arrows).

testing she was found to have global impairment with an MMSE [4] score of 4/30 and demonstrated visual agnosia. She was unable to complete the remainder of the neuropsychological battery. On the NPI-Q [5] she was found to have symptoms of severe depression and moderate agitation, repetitive behaviors, and changes in nighttime and appetitive behaviors. Clinical Dementia Rating Scale [6] score was 2 (sum of boxes score 13), representing moderate dementia. She had progressive deterioration subsequently with increased difficulties in vision, ambulation, and the onset of hallucinations. She died 3 months after the evaluation at age 65 with the proximal cause of her death being unknown and no autopsy was performed.

3.2. Family history

The patient's mother was affected by a similar illness, beginning at age 59 with death at age 64. By family report, the mother's illness was characterized by early loss of hygiene and driving privileges, and also with prosopagnosia and a shuffling gait though with more severe communication problems than the index patient. The patient's father died without dementia at age 85 and there were no other affected persons on her mother's side. The maternal grandfather died at age 47 of a myocardial infarction and the maternal grandmother lived to be 88 years of age without dementia.

The patient is the oldest of 5 siblings. One brother had memory problems with an age of onset of 55 years. At age 56 he was noted to have depression, had an MMSE score of 25/30 and was noted to have mild apraxia. He was thought to meet criteria for mild cognitive impairment. An extensive evaluation for reversible causes of cognitive impairment was unremarkable. At age 57 an EEG, MRI, and FDG-PET scan were reported as being normal. Between ages 56 and 57 he had undergone repeated neuropsychological testing by the same psychologist and was found to have substantial decline between the two intervals, qualifying for a diagnosis of dementia at the time of the later testing.

Two older sisters, age 59 and 61, were without cognitive decline. They participated in the DIAN and therefore underwent comprehensive evaluations.

3.3. Chemical and imaging biomarker evaluations

A research MRI from the index patient demonstrated diffuse atrophy which was most dramatic in the lateral temporal lobes and insulae bilaterally (See Fig. 1). The FDG-PET scan showed hypometabolism in parieto-temporal areas (Fig. 2). Amyloid imaging was not performed. A lumbar puncture was performed which revealed a CSF Aβ42 level of 391.6 (95th CI for NCs, 861–1008), p-tau of 55.7 (NCs, range 17–21), and total tau of 155.4 (NCs, range 52–68, all pg/ml). The two clinically- and genetically-(see below) unaffected sisters had corresponding mean values of 1143.0 (Aβ42), 21.5 (p-tau), and 56.4 (t-tau). These two unaffected sisters had negative PiB scans.

3.4. Genetic testing

Genetic testing for a mutation in the *PSEN1* gene was performed on the index patient through a commercial provider. This revealed a G to A transition at nucleotide position 689 which results in an amino acid change from serine to asparagine at codon 230 (S230N) in the fifth transmembrane portion of the protein. This variant had not previously been reported and was not found in the clinical provider's own series of 13,006 chromosomes, the Exome Variant Server (http://evs.gs.washington.edu/EVS/) or ExAC (http://exac.broadinstitute.org). It causes a change in an amino acid that is conserved across mammals as well as in turkeys and zebrafish,

and in human *PSEN2*. It is predicted to be "not tolerated" by SIFT (http://sift.jcvi.org) and is described as "Probably Damaging" by PolyPhen-2 (http://genetics.bwh.harvard.edu/pph2/). No mutations have been previously described at this codon, but pathogenic mutations have been described at neighboring codons 229 [7] and 231 [8,9].

Subsequent testing for this mutation in UCLA's Orphan Disease laboratory confirmed the presence of this same change in the index patient's affected brother. The two clinically unaffected sisters who participated in the DIAN underwent clinical testing and were negative for the S230N *PSEN1* mutation. Both were found to be cognitively normal.

4. Discussion

We report a family with a novel mutation in *PSEN1* causing onset of symptoms of neurodegeneration at a mean age of 57. Though amyloid imaging and neuropathological verification of the diagnosis was lacking in the index patient, the diminished Aβ42 and elevated p-tau and total tau in the CSF relative to her unaffected sisters support the diagnosis of Alzheimer's disease. The S230N substitution was present in both affected persons who were tested and absent in the two clinically unaffected sisters, age 59 and 61. Although it is possible that these two sisters had not yet manifested symptoms of the disease, their negative PiB scans at these ages mitigate strongly against the likelihood that they were in the prodromal phase of the disease[10,11]. We therefore demonstrate co-segregation of AD and associated biomarker changes with the S230N *PSEN1* mutation. This mutation would therefore qualify as probably pathogenic according to the criteria by Guerreiro et al. [12]. The lack of this variant in control chromosomes, conservation across species and in human *PSEN2*, and predicted pathogenicity *in silico* provide further support for the causative nature of this substitution for autosomal dominant AD.

Our index patient had the somewhat atypical feature of visual agnosia with prosopagnosia which was associated with bilateral lateral temporal lobe atrophy on MRI. Though the degree and nature of these visuoperceptual problems were not strictly characterized, they were clinically relevant in that they interfered with her daily activities. Agnosia is not uncommon [13] but prosopagnosia has not to our knowledge been reported in ADAD. When present in other neurodegenerative conditions (e.g. the semantic variant of frontotemporal dementia), prosopagnosia is associated with lateral temporal lobe atrophy, particularly on the right side [14]. The index patient also demonstrated hoarding behavior which has been associated with lateral temporal lobe atrophy in behavioral variant frontotemporal dementia [15]. Significant Parkinsonism was also present which is not infrequent in ADAD [13]. Unfortunately, pathological assessment for the presence of Lewy body pathology was not performed.

5. Conclusions

In this report we describe co-segregation of a novel *PSEN1* mutation with ADAD and associated biomarkers, providing strong evidence for its pathogenicity. Age of symptom onset was around 57 years and the index patient demonstrated prosopagnosia and hoarding behaviors associated with a greater degree of lateral temporal lobe and insular atrophy than typically seen in ADAD. Presymptomatic persons from families such as this at-risk for ADAD are appropriate candidates for intervention studies to prevent the disease [16].

Acknowledgements

The authors would like to thank Giovanni Coppola, M.D. for guidance.

Funding: This study was supported by the Dominantly Inherited Alzheimer Network NIA U19 AG032438, U01 AG05121, the UCLA Clinical Translational Research Institute</GN2>UL1-RR033176</GN2>, Alzheimer's Disease Research Center Grants P50 AG-16570, P50 AG-005142, U01 AG-051218, General Clinical Research Centers ProgramM01-RR00865, and the Easton Consortium for Alzheimer's Disease Drug Discovery and Biomarker Development.

References

[1] J.C. Morris, P.S. Aisen, R.J. Bateman, T.L. Benzinger, N.J. Cairns, A.M. Fagan, B. Ghetti, A.M. Goate, D.M. Holtzman, W.E. Klunk, E. McDade, D.S. Marcus, R.N. Martins, C.L. Masters, R. Mayeux, A. Oliver, K. Quaid, J.M. Ringman, M.N. Rossor, S. Salloway, P.R. Schofield, N.J. Selsor, R.A. Sperling, M.W. Weiner, C. Xiong, K.L. Moulder, V.D. Buckles, Developing an international network for alzheimer research: the dominantly inherited alzheimer network, Clin. Investig. (Lond) 2 (2012) 975–984.

[2] M.A. Mintun, G.N. Larossa, Y.I. Sheline, C.S. Dence, S.Y. Lee, R.H. Mach, W.E. Klunk, C.A. Mathis, S.T. DeKosky, J.C. Morris, [11C]PIB in a nondemented population: potential antecedent marker of Alzheimer disease, Neurology 67 (2006) 446–452.

[3] Z.S. Nasreddine, N.A. Phillips, V. Bedirian, S. Charbonneau, V. Whitehead, I. Collin, J.L. Cummings, H. Chertkow, The Montreal Cognitive Assessment, MoCA: a brief screening tool for mild cognitive impairment, J. Am. Geriatr. Soc. 53 (2005) 695–699.

[4] S.E. Folstein, Mini-mental state. A practical method for grading the cognitive state of patients for the clinician, J. Psychiatr. Res. 12 (1975) 189–198.

[5] D.I. Kaufer, J.L. Cummings, P. Ketchel, V. Smith, A. MacMillan, T. Shelley, O.L. Lopez, S.T. DeKosky, Validation of the NPI-Q, a brief clinical form of the Neuropsychiatric Inventory, J. Neuropsychiatry Clin. Neurosci. 12 (2000) 233–239.

[6] J.C. Morris, Clinical dementia rating: a reliable and valid diagnostic and staging measure for dementia of the Alzheimer type, Int. Psychogeriatr. 9 (Suppl 1) (1997) 173–176 (discussion 177–178).

[7] J.C. Janssen, J.A. Beck, T.A. Campbell, A. Dickinson, N.C. Fox, R.J. Harvey, H. Houlden, M.N. Rossor, J. Collinge, Early onset familial Alzheimer's disease: mutation frequency in 31 families, Neurology 60 (2003) 235–239.

[8] D. Campion, C. Dumanchin, D. Hannequin, B. Dubois, S. Belliard, M. Puel, C. Thomas-Anterion, A. Michon, C. Martin, F. Charbonnier, G. Raux, A. Camuzat, C. Penet, V. Mesnage, M. Martinez, F. Clerget-Darpoux, A. Brice, T. Frebourg, Early-onset autosomal dominant Alzheimer disease: prevalence, genetic heterogeneity, and mutation spectrum, Am. J. Hum. Genet. 65 (1999) 664–670.

[9] M. Cruts, C.M. van Duijn, H. Backhovens, M. Van den Broeck, A. Wehnert, S. Serneels, R. Sherrington, M. Hutton, J. Hardy, P.H. St George-Hyslop, A. Hofman, C. Van Broeckhoven, Estimation of the genetic contribution of presenilin-1 and -2 mutations in a population-based study of presenile Alzheimer disease, Hum. Mol. Genet. 7 (1998) 43–51.

[10] D.C. Ryman, N. Acosta-Baena, P.S. Aisen, T. Bird, A. Danek, N.C. Fox, A. Goate, P. Frommelt, B. Ghetti, J.B. Langbaum, F. Lopera, R. Martins, C.L. Masters, R.P. Mayeux, E. McDade, S. Moreno, E.M. Reiman, J.M. Ringman, S. Salloway, P.R. Schofield, R. Sperling, P.N. Tariot, C. Xiong, J.C. Morris, R.J. Bateman, Symptom onset in autosomal dominant Alzheimer disease: a systematic review and meta-analysis, Neurology 83 (2014) 253–260.

[11] R.J. Bateman, C. Xiong, T.L. Benzinger, A.M. Fagan, A. Goate, N.C. Fox, D.S. Marcus, N.J. Cairns, X. Xie, T.M. Blazey, D.M. Holtzman, A. Santacruz, V. Buckles, A. Oliver, K. Moulder, P.S. Aisen, B. Ghetti, W.E. Klunk, E. McDade, R.N. Martins, C.L. Masters, R. Mayeux, J.M. Ringman, M.N. Rossor, P.R. Schofield, R.A. Sperling, S. Salloway, J.C. Morris, Clinical and biomarker changes in dominantly inherited Alzheimer's disease, N. Engl. J. Med. 367 (2012) 795–804.

[12] R.J. Guerreiro, M. Baquero, R. Blesa, M. Boada, J.M. Bras, M.J. Bullido, A. Calado, R. Crook, C. Ferreira, A. Frank, T. Gomez-Isla, I. Hernandez, A. Lleo, A. Machado, P. Martinez-Lage, J. Masdeu, L. Molina-Porcel, J.L. Molinuevo, P. Pastor, J. Perez-Tur, R. Relvas, C.R. Oliveira, M.H. Ribeiro, E. Rogaeva, A. Sa, L. Samaranch, R. Sanchez-Valle, I. Santana, L. Tarraga, F. Valdivieso, A. Singleton, J. Hardy, J. Clarimon, Genetic screening of Alzheimer's disease genes in Iberian and African samples yields novel mutations in presenilins and APP, Neurobiol. Aging 31 (2010) 725–731.

[13] M. Tang, D.C. Ryman, E. McDade, M.S. Jasielec, V.D. Buckles, N.J. Cairns, A.M. Fagan, A. Goate, D.S. Marcus, C. Xiong, R.F. Allegri, J.P. Chhatwal, A. Danek, M.R. Farlow, N.C. Fox, B. Ghetti, N.R. Graff-Radford, C. Laske, R.N. Martins, C.L. Masters, R.P. Mayeux, J.M. Ringman, M.N. Rossor, S.P. Salloway, P.R. Schofield, J.C. Morris, R.J. Bateman, Dominantly Inherited Alzheimer Networ, Neurological manifestations of autosomal dominant familial Alzheimer's disease: a comparison of the published literature with the Dominantly

Inherited Alzheimer Network observational study (DIAN-OBS), Lancet Neurol. 15 (2016) 1317–1325.
[14] K.A. Josephs, J.L. Whitwell, D.S. Knopman, B.F. Boeve, P. Vemuri, M.L. Senjem, J.E. Parisi, R.J. Ivnik, D.W. Dickson, R.C. Petersen, C.R. Jack Jr., Two distinct subtypes of right temporal variant frontotemporal dementia, Neurology 73 (2009) 1443–1450.
[15] D.C. Perry, J.L. Whitwell, B.F. Boeve, V.S. Pankratz, D.S. Knopman, R.C. Petersen, C.R. Jack Jr., K.A. Josephs, Voxel-based morphometry in patients with obsessive-compulsive behaviors in behavioral variant frontotemporal dementia, Eur. J. Neurol. 19 (2012) 911–917.
[16] J.M. Ringman, J. Grill, Y. Rodriguez-Agudelo, M. Chavez, C. Xiong, Commentary on a roadmap for the prevention of dementia II: Leon Thal Symposium 2008. Prevention trials in persons at risk for dominantly inherited Alzheimer's disease: opportunities and challenges, Alzheimers Dementia 5 (2009) 166–171.